

# UC DAVIS DERMATOPATHOLOGY SERVICE

**UCDAVIS**  
HEALTH SYSTEM

MAXWELL A. FUNG, MD, DIRECTOR  
THOMAS H. KONIA, MD  
Department of Dermatology  
3301 C Street, Suite 1450  
Sacramento, California 95816  
Phone: (916) 734-6373 Toll Free: (866) 323-9061 Fax: (916) 703-5159

**UCDAVIS**  
SCHOOL OF MEDICINE

## Dermatopathology Report

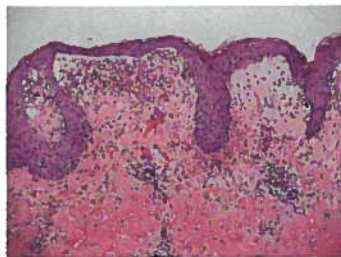
**PATIENT NAME:** **PATH NUMBER:** DS14-02529  
**DOB:** Service: 3/31/2014  
Received: 3/31/2014  
Age/Sex: Reported: 4/1/2014  
Physician: Physician Fax:  
Physician Phone: CC Fax Number:  
Copy To:  
CC Phone Number:

**Clinical Data:** A,B) Pink pruritic/vesicular papules, DDx: dermatitis herpetiformis, BP, drug reaction, other.

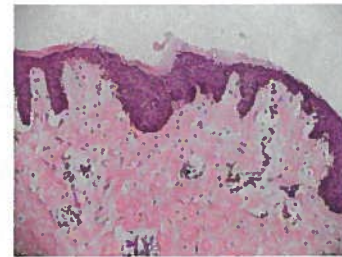
### DIAGNOSIS:

- A SKIN, LEFT AXILLA, MEDIAL (PUNCH BIOPSY)  
DERMATITIS HERPETIFORMIS
- B SKIN, LEFT AXILLA, LATERAL, PERILESIONAL (PUNCH BIOPSY)  
DIRECT IMMUNOFLUORESCENCE: GRANULAR DEPOSITION OF IGA ALONG THE  
BASEMENT MEMBRANE ZONE, CONSISTENT WITH DERMATITIS HERPETIFORMIS

A



B: H&E



**Specimen:** A SKIN, LEFT AXILLA, MEDIAL  
B SKIN, LEFT AXILLA, LATERAL, PERILESIONAL

### Gross

- A Received in formalin, cylindrical skin segment, 0.2 x 0.3 cm, entirely submitted in 1 block in a nylon bag.mu
- B Received for immunofluorescence studies, cylindrical skin segment, 0.3 x 0.4 cm, entirely submitted in 1 block.jf

**Microscopic Description**

- A Sections show a subepidermal split with mostly neutrophils and also fibrin and eosinophils within the blister cavity and upper dermis.
- B Cryostat sections stained with fluorescein-conjugated antibodies to IgG, IgM, IgA, C3, fibrinogen, and albumin were performed. There is granular IgA along the basement membrane zone, accentuated within dermal papillae, variable concomitant fibrinogen within dermal papillae, and no other significant epidermal, junctional, or perivascular reactivity. The immunohistochemical tests were developed and their performance characteristics determined by the UC Davis Dermatopathology Service. This laboratory is certified under the Clinical Laboratory Improvement Amendments of 1988 (CLIA-88) as qualified to perform high complexity clinical laboratory testing.

**ICD9:** A. 694.0 B. 694.0

**CPT:** A. 88305 B. 88346 x 6

Electronically Signed By:

**Maxwell A. Fung, MD**  
**Dermatopathologist**